

Anterolateral Ligament Repair With Suture Tape Augmentation



Christiaan H. W. Heusdens, M.D., Graeme P. Hopper, M.B.Ch.B., M.Sc., M.R.C.S.,
Lieven Dossche, M.D., and Gordon M. Mackay, M.D.

Abstract: Recent insights into the structure and function of the anterolateral ligament (ALL) of the knee has resulted in a recognition of its contribution in rotational control of the knee. Several ALL reconstruction techniques have been described in the literature. This article describes, with video illustration, a percutaneous repair technique using suture tape augmentation. A tendon graft is not needed. This technique allows early mobilization and encourages natural healing of the ligament by protecting the ligament during the healing phase as a secondary stabilizer.

Although the debate on the exact anatomy and function of the anterolateral complex is ongoing, recent insights into the structure and function of the anterolateral ligament (ALL)¹ of the knee have resulted in a growing evidence of its role in rotational control of the knee. The ALL has been identified as a contributor to the anterolateral rotational stability of the knee,^{2,3} and there is a close association with anterior cruciate ligament (ACL) ruptures.⁴ Several indications for ALL reconstruction or repair have been described: an ALL rupture combined with an ACL rupture, chronic ACL lesions, an ACL rupture with a grade 3 pivot shift, high-demanding athletes, and revision ACL surgery.⁵

Multiple ALL reconstruction and repair techniques in combination with ACL reconstruction have been described in the literature.⁶

There is ongoing debate on the exact location of the ALL, especially the femoral origin, which is important if we want to perform an anatomical reconstruction.^{1,7-10} Several recent biomechanical studies agree that the femoral origin is posterior and proximal to the lateral epicondyle.^{7,8,11} The ALL then crosses superficial to the lateral collateral ligament (LCL) to its tibial insertion, which is halfway between the Gerdy tubercle and the anterior margin of the fibular head, 9.5 mm distal to the joint line.⁸

ALL repair with suture tape augmentation does not use a tendon graft. Postoperatively, patients are mobilized early without a brace and with crutches as needed. An ultrahigh-strength 2-mm-width tape is used to bridge the ligament, and knotless bone anchors secure the augmentation. This technique reinforces the ligament as a secondary stabilizer, encouraging natural healing of the ligament by protecting it during the healing phase and supporting early mobilization.

Surgical Technique

This Technical Note describes ALL repair with suture tape augmentation (Video 1). This technique can be used in acute injuries as well as chronic ruptures of the ALL. It is a percutaneous technique, which can be performed within 5 minutes.

The suture tape augmentation consists of an ultrahigh-strength 2-mm-width tape (FiberTape, Arthrex, Naples, FL) and 2 bone anchors (SwiveLock, Arthrex). The ultrahigh-strength tape is made of a long-chain ultrahigh-molecular-weight polyethylene. The

From the Antwerp University Hospital (C.H.W.H., L.D.), Edegem, Belgium; Institute of Infection, Immunity and Inflammation (G.P.H.), University of Glasgow, Glasgow, Scotland; and University of Stirling (G.M.M.), Stirling, Scotland.

The authors report the following potential conflicts of interest or sources of funding: C.H.W.H. receives grants for the Antwerp University Hospital from the Research Foundation Flanders (FWO, reference T001017N), outside the submitted work. L.D. receives institutional grants from Mathys Medical for consultancy regarding hip replacement. G.M.M. receives institutional grants from Arthrex for teaching as a consultant and has a patent for the internalBrace, and royalties relate only to surgical internalBrace kits, which are not available for ALL repair or used for this study. Full ICMJE author disclosure forms are available for this article online, as [supplementary material](#).

Received July 5, 2018; accepted August 9, 2018.

Address correspondence to Christiaan H.W. Heusdens, M.D., University of Antwerpen, Wilrijkstraat 10, 2650, Edegem, Belgium. E-mail: krik.heusdens@uza.be

© 2018 by the Arthroscopy Association of North America. Published by Elsevier. This is an open access article under the CC BY-NC-ND license (<http://creativecommons.org/licenses/by-nc-nd/4.0/>).

2212-6287/18839

<https://doi.org/10.1016/j.eats.2018.08.016>

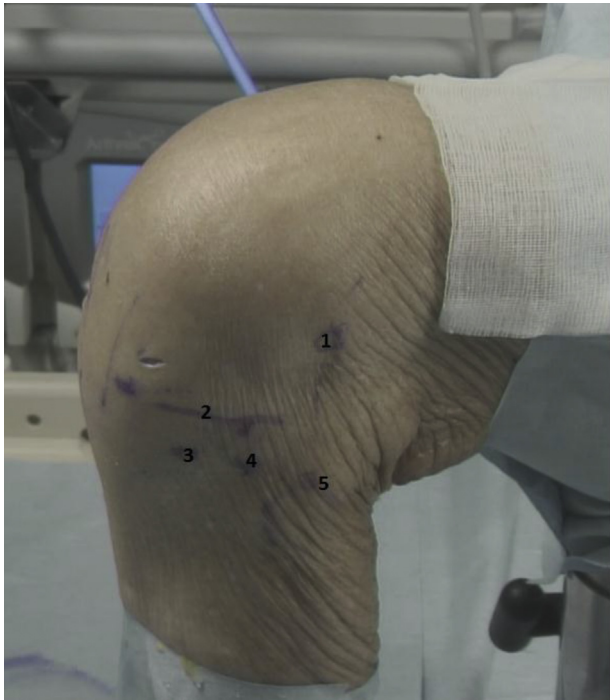


Fig 1. Left knee, lateral view, with marking on the lateral femoral epicondyle (1), the joint line (2), the Gerdy tubercle (3), anterolateral ligament tibial insertion (4), and the anterior margin of the fibular head (5).

tape is fixed in the femur with a 4.75-mm bone anchor and in the tibia with a 3.5-mm bone anchor. This procedure is often performed in combination with ACL repair or reconstruction and would then be performed as the second procedure.

Patient Positioning and Preoperative Marking

The patient is placed in a supine position with a tourniquet on the upper thigh. As the technique is often combined with an ACL procedure, the injured leg can be placed in the surgeon’s preferred position for ACL procedure.

The lateral femoral epicondyle, the distal joint line, Gerdy tubercle, and the anterior margin of the fibular

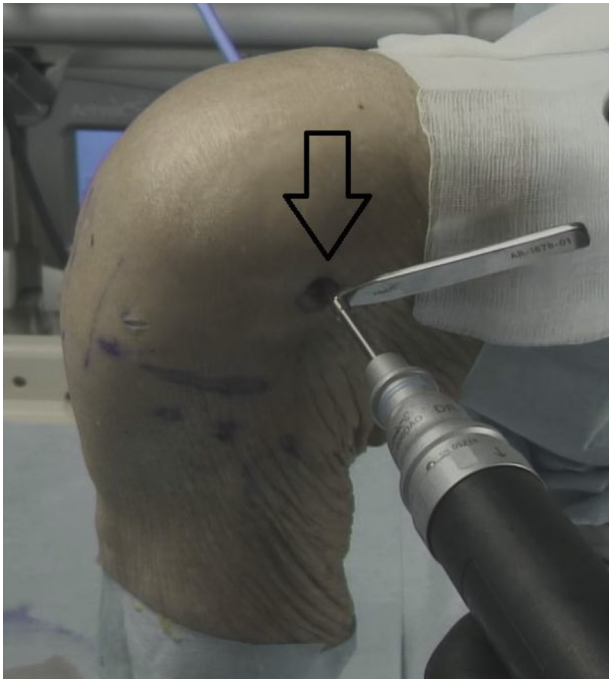


Fig 2. Left knee, lateral view. Predrilling the femoral origin of the anterolateral ligament (arrow), approximately 7.0 mm posterior and proximal to the lateral femoral epicondyle.

head are palpated and marked. The tibial insertion is marked halfway between the Gerdy tubercle and the anterior margin of the fibular head, 1 cm distal to the joint line (Fig 1).

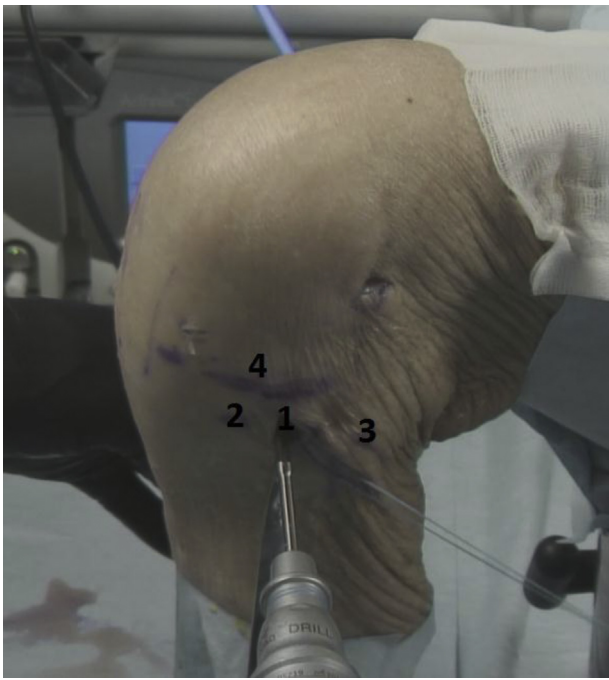
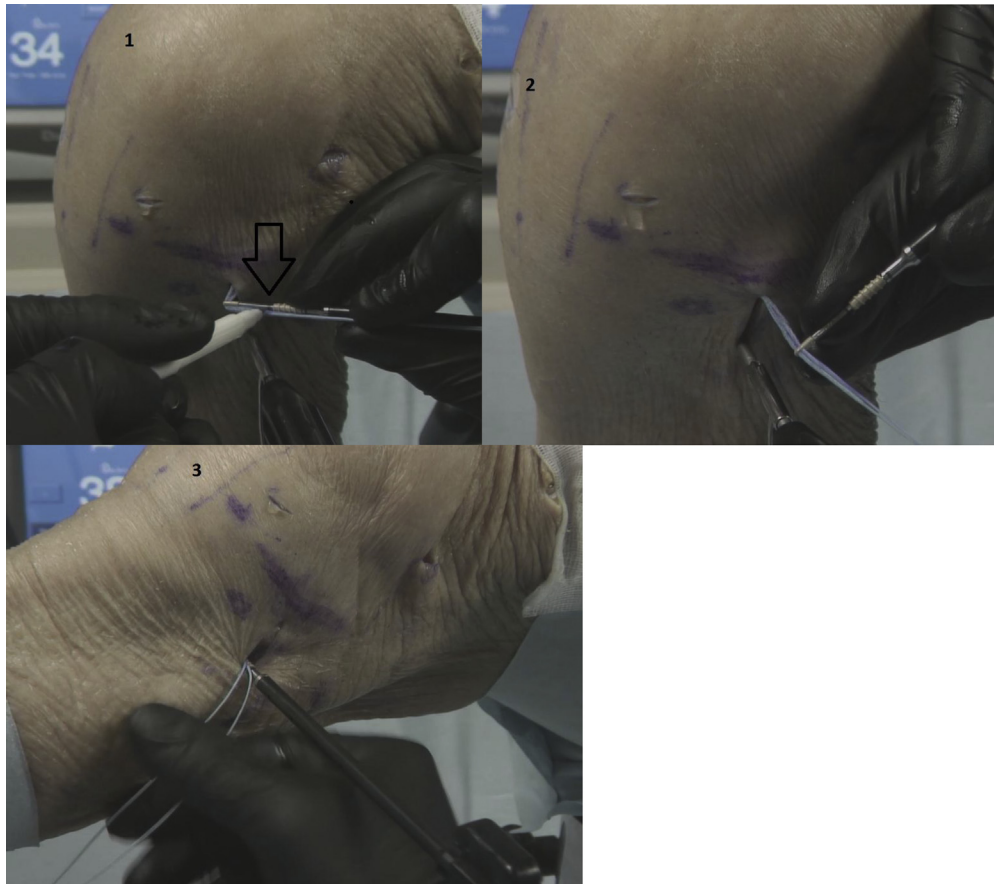


Fig 3. Left knee, lateral view. Predrilling the tibial insertion (1), halfway between Gerdy tubercle (2) and the anterior margin of the fibular head (3), 1 cm distal to the joint line (4). The ultrahigh-strength tape is temporarily being held aside, so as not to interfere with the drilling.

Table 1. Anterolateral Ligament Repair With Suture Tape Augmentation Summary

Step	Description
1. Place a proximal 4.75-mm bone anchor loaded with ultrahigh-strength tape	Drill and tap 7 mm posterior and proximal to the lateral femoral epicondyle
2. Create a tunnel for the ultrahigh-strength tape	Break adhesions under the iliotibial band by moving the hemostat distally and sideways
3. Fixate the ultrahigh-strength tape distally with a 3.5-mm bone anchor	Drill and tap 1 cm distal to joint line, halfway between the Gerdy tubercle and the fibular head, check for isometry and full range of motion

Fig 4. Left knee, lateral view. The ultrahigh-strength tape is marked at the beginning of the screw of the bone anchor (arrow) (1) and is then repositioned in the eye of the bone anchor at the marked level (2) followed by placement of the bone anchor in the drill hole (3).



ALL Repair With Suture Tape Augmentation

A 1.5- to 2-cm incision is made starting over the lateral femoral epicondyle in a posterior and proximal direction. The iliotibial band is split. The femoral origin of the ALL is approximately 7 mm posterior and proximal to the lateral epicondyle. After pre-drilling, with a 4.5-mm drill and a 20-mm drill stop, followed by tapping, a 4.75-mm bone anchor loaded with an ultrahigh-strength tape is placed (Table 1). The femoral drill hole is kept under direct vision to avoid superficial placement of the bone anchor in the bone or losing the position of the drill hole (Fig 2).

A hemostat is directed distally under the iliotibial band, superficial to the lateral collateral ligament. To break any adhesions, the hemostat is distally moved sideways to create a tunnel for the ultrahigh-strength tape. The skin is incised over the tip of the hemostat at the previous marked ALL insertion. Using a lead suture transported by the hemostat, the ultrahigh-strength tape is brought to the tibial incision. Under direct vision of the bony ALL insertion location, the 3.5-mm bone anchor is predrilled and tapped after taking the knee through a range of motion, with the tap left in place. A 3.5-mm anchor gives sufficient strength in the strong tibial bone and is preferred over larger sizes given the proximity of the joint (Fig 3).

The ultrahigh-strength tape is loaded in the distal bone anchor and marked at the beginning of the screw of the bone anchor, repositioned in the eye of the bone anchor at the marked level, and finally the bone anchor is placed in the drill hole (Fig 4). In chronic ALL ruptures, the ALL can be advanced with the No. 0 suture, which is loaded in the bone anchor, to regain its natural tension.

Postoperative Rehabilitation

Most patients have a combined ACL and ALL procedure, and a standard ACL rehabilitation program is recommended. Patients who receive an isolated ALL repair are allowed to fully weight-bear with crutches as required. Physical therapy focuses on early range of movement, muscle control, and restoration of function.

Table 2. Advantages and Disadvantages

Advantages	Disadvantages
No interference with ACL fixation	Additional procedure
No donor harvest	Synthetic augmentation
Quick procedure, therefore limited theater time	Unforgiving if overconstrained
Easily reproducible	

ACL, anterior cruciate ligament.

Table 3. Risks and Limitations

Risks and Limitations
Excessive tension of the ultrahigh-strength tape can cause failure of the bone anchor or lateral meniscal pathology.
Nonisometric position of the bone anchors can lead to a poor biomechanical outcome.

This is facilitated by the limited pain and swelling, allowing accelerated early-phase rehabilitation. No brace is required.

Discussion

This Technical Note describes the ALL repair with suture tape augmentation technique. It is a simple, minimally invasive, and quick procedure, which provides additional anterolateral rotational stability and is often performed together with an ACL repair or reconstruction (Table 2). This technique encourages natural healing of the ALL. In chronic cases, the ALL can regain its natural tension by tensioning the ALL.

In the past, anterolateral extra-articular stabilization was performed more frequently. Many different techniques have been used. Most of these techniques were nonanatomical reconstructions and used a part of the iliotibial band.¹² Most of them, however, have been abandoned because of the improvements in arthroscopic ACL reconstruction. Nowadays, several techniques for anatomical ALL reconstruction have been described.⁶ Many of these techniques use a tendon autograft (semitendinosus or gracilis) or allograft. With ALL repair with suture tape augmentation, a tendon graft is not used; the native ligament is repaired in the acute case and retensioned in case of a chronic ALL rupture. As a tendon graft is not required, the risk of morbidity associated with harvesting is absent.

One of the risks of this technique is excessive tensioning of the ultrahigh-strength tape (Table 3). This can cause failure of the bone anchor or lateral meniscal pathology. A nonanatomic or nonisometric position of the anchor can lead to a poor biomechanical outcome.

The ALL has been identified as a contributor to the anterolateral rotational stability of the knee.^{2,3} By repairing or reinforcing the ALL, more anterolateral stability is provided, and a lower rerupture rate of the ACL can be expected. Helito et al described better results in their ACL + ALL reconstruction group versus an isolated ACL reconstruction group in patients who were treated for a chronic ACL lesion. The ACL + ALL group had a positive pivot shift test in 9.1% and no reruptures versus, respectively, 35.3% and 7.3%.¹³

The technique described in this Technical Note has been described for many other ligaments, including ACL repair.¹⁴ The suture tape augmentation acts as a safety belt for the repaired or healing ligament and protects it against high strains that would impair the

healing or even cause a rerupture during the healing process. Furthermore, the augment supports early mobilization. Additional outcome data for this ALL repair technique is needed to prove the concept.

References

1. Claes S, Vereecke E, Maes M, Victor J, Verdonk P, Bellemans J. Anatomy of the anterolateral ligament of the knee. *J Anat* 2013;223:321-328.
2. Parsons EM, Gee AO, Spiekerman C, Cavanagh PR. The biomechanical function of the anterolateral ligament of the knee. *Am J Sports Med* 2015;43:669-674.
3. Sonnery-Cottet B, Lutz C, Daggett M, et al. The involvement of the anterolateral ligament in rotational control of the knee. *Am J Sports Med* 2016;44:1209-1214.
4. Van Dyck P, Clockaerts S, Vanhoenacker FM, et al. Anterolateral ligament abnormalities in patients with acute anterior cruciate ligament rupture are associated with lateral meniscal and osseous injuries. *Eur Radiol* 2016;26:3383-3391.
5. Sonnery-Cottet B, Thaunat M, Freychet B, Pupim BH, Murphy CG, Claes S. Outcome of a combined anterior cruciate ligament and anterolateral ligament reconstruction technique with a minimum 2-year follow-up. *Am J Sports Med* 2015;43:1598-1605.
6. Roessler PP, Schuttler KF, Heyse TJ, Wirtz DC, Efe T. The anterolateral ligament (ALL) and its role in rotational extra-articular stability of the knee joint: A review of anatomy and surgical concepts. *Arch Orthop Trauma Surg* 2016;136:305-313.
7. Daggett M, Ockuly AC, Cullen M, et al. Femoral origin of the anterolateral ligament: An anatomic analysis. *Arthroscopy* 2016;32:835-841.
8. Kennedy MI, Claes S, Fuso FA, et al. The anterolateral ligament: An anatomic, radiographic, and biomechanical analysis. *Am J Sports Med* 2015;43:1606-1615.
9. Dodds AL, Halewood C, Gupte CM, Williams A, Amis AA. The anterolateral ligament: Anatomy, length changes and association with the Second fracture. *J Bone Joint Br* 2014;96:325-331.
10. Caterine S, Litchfield R, Johnson M, Chronik B, Getgood A. A cadaveric study of the anterolateral ligament: Re-introducing the lateral capsular ligament. *Knee Surg Sports Traumatol Arthrosc* 2015;23:3186-3195.
11. Runer A, Birkmaier S, Pamminger M, et al. The anterolateral ligament of the knee: A dissection study. *Knee* 2016;23:8-12.
12. Hewison CE, Tran MN, Kaniki N, Remtulla A, Bryant D, Getgood AM. Lateral extra-articular tenodesis reduces rotational laxity when combined with anterior cruciate ligament reconstruction: A systematic review of the literature. *Arthroscopy* 2015;31:2022-2034.
13. Helito CP, Camargo DB, Sobrado MF, et al. Combined reconstruction of the anterolateral ligament in chronic ACL injuries leads to better clinical outcomes than isolated ACL reconstruction [published online April 2, 2018]. *Knee Surg Sports Traumatol Arthrosc*. doi:10.1007/s00167-018-4934-2.
14. Heusdens C, Hopper G, Dossche L, Mackay G. Anterior cruciate ligament repair using independent suture tape reinforcement. *Arthrosc Tech* 2018;7:e747-e753.