

Posterior Cruciate Ligament Repair With Suture Tape Augmentation



Graeme P. Hopper, M.B.Ch.B., M.Sc., M.R.C.S., Christiaan H. W. Heusdens, M.D.,
Lieven Dossche, M.D., and Gordon M. Mackay, M.D.

Abstract: The posterior cruciate ligament (PCL) acts as the primary restraint to posterior tibial translation of the knee. Injuries to the PCL are rare in isolation and more often are associated with multiligament injuries to the knee. Several PCL reconstruction and PCL repair techniques have been described in the literature, but no single technique has been shown to be the most superior. Internal bracing with suture tape augmentation encourages natural healing and allows early mobilization. This article describes, with video illustration, PCL repair with suture tape augmentation.

The posterior cruciate ligament (PCL) is a crucial stabilizer of the knee, functioning as the primary restraint to posterior tibial translation.¹ It originates on the medial femoral condyle and inserts on the posterior intercondylar area of the tibia.² The PCL is composed of 2 bundles, an anterolateral bundle and a posteromedial bundle.³ PCL injury accounts for up to 20% of injuries to the ligaments around the knee.⁴ However, it has been reported that isolated injuries to the PCL are rare and most occur in the multiligament knee injury setting.³

An increased incidence of osteoarthritis in patients with PCL deficiency has been reported in the literature.⁵

Consequently, one of the main treatment aims in patients with a PCL injury should be to restore the function of the ligament as closely to normal as possible. Surgery is therefore recommended in patients with grade III PCL tears, symptomatic chronic tears, and PCL tears associated with other ligamentous knee injuries. Several procedures have been described in the literature, with PCL reconstruction procedures being the most widely used option. We describe PCL repair with suture tape augmentation that encourages healing and allows early mobilization (Video 1).

Surgical Technique

The patient is placed in the supine position, and a tourniquet is placed on the upper thigh. The injured leg is prepared and draped in the surgeon's preferred position, similarly to a PCL reconstruction procedure. Standard anteromedial and anterolateral portals are used. A PassPort cannula (Arthrex) is inserted into the anteromedial portal, and an accessory posteromedial portal is used for safe visualization and soft-tissue management. A general inspection of the joint is performed, and the PCL tear is identified. If required, meniscal or cartilage surgery is then undertaken.

The PCL is elevated and traced to its tibial insertion, and the fibers are retained. This still allows for safe and adequate exposure by pushing the residual PCL fibers and other posterior structures posteriorly. A 3.5-mm tunnel is then drilled using a standard PCL guide after a small anteromedial incision is made over the proximal tibia. The drill is advanced under direct vision to minimize any risk of complication. The drill sleeve is tapped in the anterior tibial cortex, and the drill is switched for a FiberStick (Arthrex). The FiberWire (Arthrex) is then

From the Institute of Infection, Immunity and Inflammation, University of Glasgow (G.P.H.), Glasgow, Scotland; Antwerp University Hospital (C.H.W.H., L.D.), Edegem, Belgium; and University of Stirling (G.M.M.), Stirling, Scotland.

The authors report the following potential conflicts of interest or sources of funding: Arthrex has facilitated the making of the video for this surgical technique. C.H.W.H. reports that Antwerp University Hospital receives support from Research Foundation Flanders (FWO) under reference T001017N not related to this manuscript. L.D. receives support from Mathys Medical for consultancy regarding hip replacement. G.M.M. is a consultant for and receives royalties from Arthrex and has a patent for the InternalBrace. Full ICMJE author disclosure forms are available for this article online, as supplementary material.

Received July 6, 2018; accepted August 10, 2018.

Address correspondence to Graeme P. Hopper, M.B.Ch.B., M.Sc., M.R.C.S., Institute of Infection, Immunity and Inflammation, College of Medical, Veterinary and Life Sciences, University of Glasgow, 120 University Place, Glasgow, Scotland, G12 8TA. E-mail: gordonmmackay@gmail.com

© 2018 by the Arthroscopy Association of North America. Published by Elsevier. This is an open access article under the CC BY-NC-ND license (<http://creativecommons.org/licenses/by-nc-nd/4.0/>).

2212-6287/18843

<https://doi.org/10.1016/j.eats.2018.08.022>

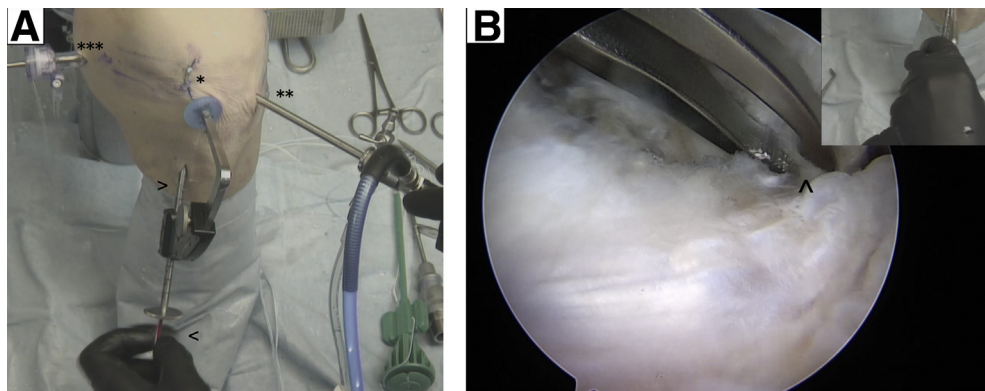


Fig 1. (A) Left knee, superior view. Standard anteromedial (1 asterisk) and anterolateral (2 asterisks) portals are used with an accessory posteromedial portal (3 asterisks). A 3.5-mm tibial tunnel is then drilled using a standard posterior cruciate ligament guide (upper arrowhead), and a FiberStick (lower arrowhead) is advanced. (B) Left knee, intra-articular view on tibial side of posterior cruciate ligament. The FiberWire is grasped out of the FiberStick (carat) and retrieved through the anteromedial portal.

grasped out of the FiberStick and retrieved through the anteromedial portal (Fig 1).

The fixation point between the bundles of the PCL on the femur is identified and marked using electrosurgery, 1 cm from the articular surface, mirroring the anatomic fixation point of the PCL (Fig 2). This step ensures accuracy when the guide pin is passed. The reamer is used to allow easy passage of the femoral button (RetroButton or TightRope RT; Arthrex), which is loaded with FiberTape (Arthrex). The suture is then shuttled from the anterolateral port directly through the prepared tunnel (Fig 3). The femoral button is advanced until it locks. The suture tape is then taken onto the tibial side and secured using a 4.5-mm SwiveLock (Arthrex) with the tibia supported in a reduced position. FiberTape is an ultrahigh-strength 2-mm-wide tape, consisting of long-chain ultrahigh-molecular-weight polyethylene, and acts as an internal brace.

Securing the suture tape distally begins by predrilling with a 4.5-mm drill, followed by tapping at a point approximately 1 cm below the tibial tunnel, with the surgeon ensuring that this is performed perpendicular to the cortex. With the knee in 90° of flexion, an assistant provides anterior translation to hold the tibia in its native position with the correct tension on the PCL. The 4.75-mm anchor is then advanced to the end of the tap, and the laser line is marked, which should identify the anatomic length of the PCL. It is advanced until flush, and if there are any uncertainties, the knee can be put through a full range of movement in the reduced position because excessive tensioning can result in difficulty achieving full extension. This step is crucial to restoring the length of the PCL, and it is important for the surgical assistant to hold the tibia reduced (Fig 4).

The rehabilitation protocol could be compared with an accelerated PCL reconstruction protocol. Patients are allowed to fully bear weight with crutches as required

during the first few weeks. Physical therapy focuses on early range of movement, muscle control, and restoration of function. This is enabled by the limited pain and swelling, thereby allowing accelerated early-phase rehabilitation. Patients can perform pivoting sports when the neuromuscular function has recovered; for most patients, this occurs at around 5 to 6 months. No brace is required. Advantages and disadvantages as well as pearls and pitfalls of this technique are outlined in Tables 1 and 2.

Discussion

Multiple techniques have been described in the literature for the operative management of patients with injuries to the PCL.^{1,2,6-8} Historically, primary PCL repair was the preferred option; however, PCL reconstruction procedures are currently the most widely used option.

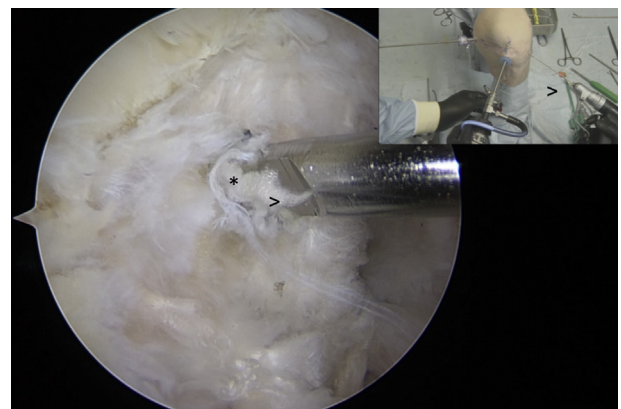


Fig 2. Left knee, intra-articular view on femoral origin of posterior cruciate ligament (PCL). The fixation point between the bundles of the PCL on the femur is identified and marked using electrosurgery, 1 cm from the articular surface, mirroring the anatomic fixation point of the PCL (1 asterisk). The reamer (carets) is then used to allow easy passage of the femoral button.

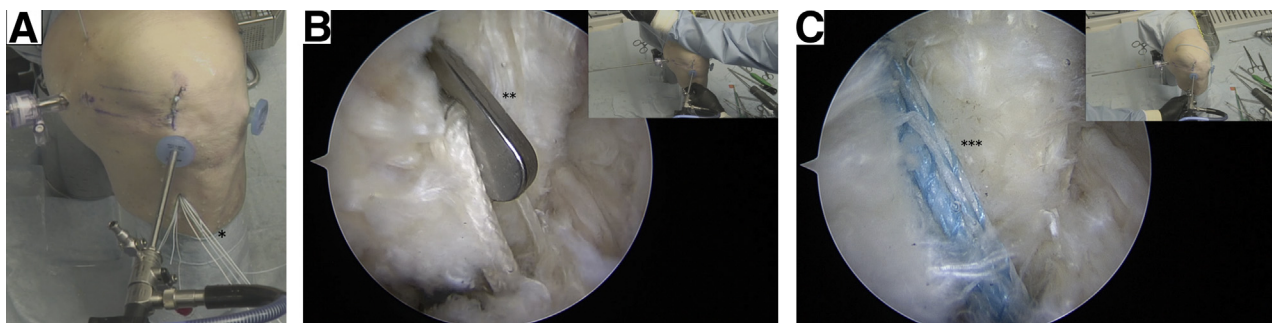


Fig 3. (A) Left knee, superior view. The button is prepared and loaded with FiberTape (1 asterisk). (B) Left knee, intra-articular view on femoral origin of posterior cruciate ligament. The suture tape is shuttled through the prepared tunnel with the button (2 asterisks) providing proximal fixation. (C) Left knee, intra-articular view on femoral origin of posterior cruciate ligament. The suture tape augmentation (3 asterisks) is shown.

Chahla et al.¹ performed a systematic review and meta-analysis of 11 studies including 441 patients to compare single- versus double-bundle PCL reconstruction. They reported improved clinical outcomes in both groups, with significantly better posterior stability and International Knee Documentation Committee scores in the double-bundle group. Belk et al.² published a systematic review and meta-analysis of 5 studies with 132 patients performed to compare PCL reconstruction with allograft versus autograft. They reported improved clinical outcomes in both groups but no differences between the groups. Del Buono et al.⁹ reviewed 34

studies with patients undergoing PCL reconstruction or PCL augmentation and found grossly equivalent results in each group. The augmentation procedures included a remnant PCL-augmenting stent procedure and double-bundle augmentation with Achilles allograft.^{10,11}

Historically, PCL repair was performed as an open procedure, with varying results.¹²⁻¹⁴ More recently, arthroscopic PCL repair has been described using a number of different techniques. Wheatley et al.¹⁵ reported satisfactory International Knee Documentation Committee and Lysholm scores at a mean follow-up of 51 months in patients who underwent repair after PCL

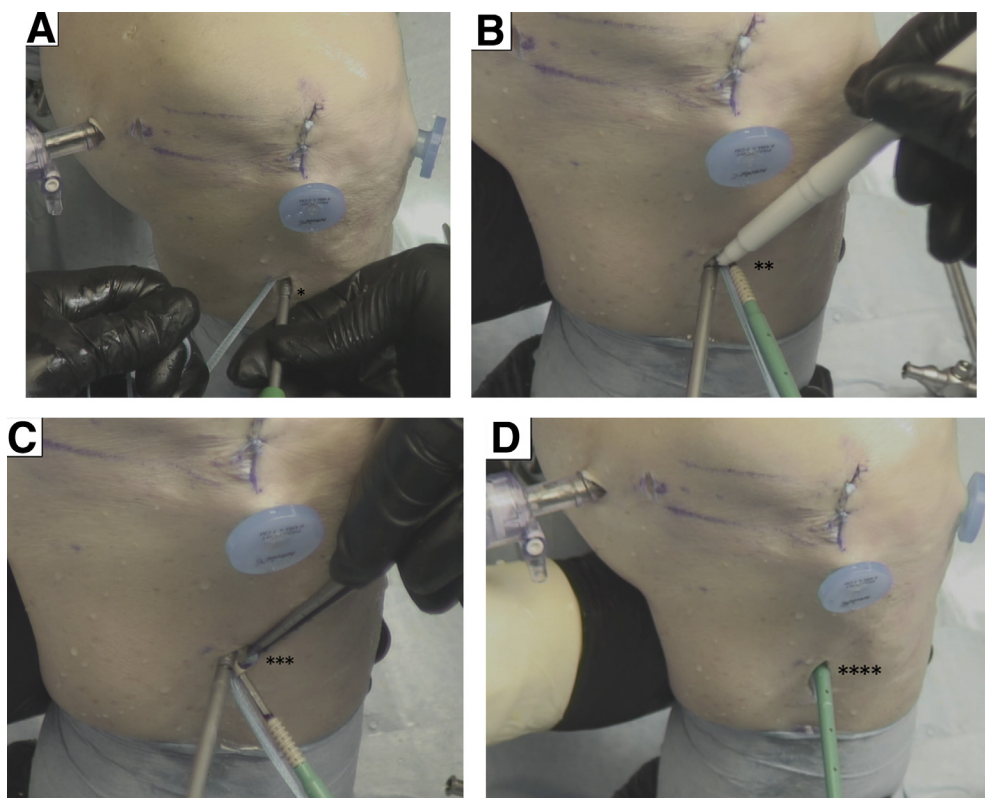


Fig 4. Left knee, anteromedial view. (A) Preparation for the distal anchor by predrilling and tapping (1 asterisk) 1 cm below the tibial tunnel. (B) The laser line is marked (2 asterisks) to identify the anatomic length of the posterior cruciate ligament. (C) Forceps (3 asterisks) are used to prevent any entanglement. (D) The anchor is advanced until it is flush with the cortex (4 asterisks).

Table 1. Advantages and Disadvantages of PCL Repair With Suture Tape Augmentation

Advantages	Disadvantages
No graft harvest required	Not all PCL ruptures can be repaired
Less invasive than PCL reconstruction	Synthetic augmentation
Facilitates rehabilitation	Reliance on biological healing
In case of rerupture, standard PCL reconstruction can be performed easily	
PCL, posterior cruciate ligament.	

soft-tissue avulsion. DiFelice et al.⁸ described a modification of this technique using suture anchors in 3 patients with soft-tissue peel-off injuries to the PCL, with satisfactory outcomes at 64 months. In addition, van der List and DiFelice⁷ recently described a PCL repair with an augmentation procedure similar to the technique we have illustrated.

PCL repair with suture tape augmentation as described in this Technical Note reinforces the ligament and acts as a secondary stabilizer. This allows natural healing of the ligament because the augmentation provides protection during the healing phase while allowing early mobilization. In addition, graft harvest is not required; therefore, muscle atrophy is avoided and the recovery is accelerated. Furthermore, the native PCL is spared, thereby providing proprioceptive properties that could contribute to an accelerated rehabilitation period. On the other hand, not all PCL ruptures can be repaired because there may be inadequate tissue; therefore, additional augmentation may be required. Moreover, it is important not to excessively tension the suture tape because this may lead to difficulties achieving full extension (Tables 1 and 2).

In conclusion, this Technical Note has discussed the technique of PCL repair with suture tape augmentation. Advantages are associated with this technique as outlined earlier, and we have observed excellent clinical

results. However, further clinical studies are necessary to determine the overall outcomes of this procedure.

References

- Chahla J, Moatshe G, Cinque ME, et al. Single-bundle and double-bundle posterior cruciate ligament reconstructions: A systematic review and meta-analysis of 441 patients at a minimum 2 years' follow-up. *Arthroscopy* 2017;33:2066-2080.
- Belk JW, Kraeutler MJ, Purcell JM, McCarty EC. Autograft versus allograft for posterior cruciate ligament reconstruction: An updated systematic review and meta-analysis. *Am J Sports Med* 2017;46:1752-1757.
- LaPrade CM, Civitarese DM, Rasmussen MT, LaPrade RF. Emerging updates on the posterior cruciate ligament: A review of the current literature. *Am J Sports Med* 2015;43:3077-3092.
- Smith C, Ajuied A, Wong F, Norris M, Back D, Davies A. The use of the ligament augmentation and reconstruction system (LARS) for posterior cruciate reconstruction. *Arthroscopy* 2014;30:111-120.
- Van de Velde SK, Bingham JT, Gill TJ, Li G. Analysis of tibiofemoral cartilage deformation in the posterior cruciate ligament-deficient knee. *J Bone Joint Surg Am* 2009;91:167-175.
- Lee DY, Park YJ. Single-bundle versus double-bundle posterior cruciate ligament reconstruction: A meta-analysis of randomized controlled trials. *Knee Surg Relat Res* 2017;29:246-255.
- van der List JP, DiFelice GS. Arthroscopic primary posterior cruciate ligament repair with suture augmentation. *Arthrosc Tech* 2017;6:e1685-e1690.
- DiFelice GS, Lissy M, Haynes P. Surgical technique: When to arthroscopically repair the torn posterior cruciate ligament. *Clin Orthop Relat Res* 2012;470:861-868.
- Del Buono A, Radmilovic J, Gargano G, Gatto S, Maffulli N. Augmentation or reconstruction of PCL? A quantitative review. *Knee Surg Sports Traumatol Arthrosc* 2013;21:1050-1063.
- Yoon KH, Bae DK, Song SJ, Lim CT. Arthroscopic double-bundle augmentation of posterior cruciate ligament using split Achilles allograft. *Arthroscopy* 2005;21:1436-1442.
- Jung YB, Jung HJ, Song KS, Kim JY, Lee HJ, Lee JS. Remnant posterior cruciate ligament-augmenting stent procedure for injuries in the acute or subacute stage. *Arthroscopy* 2010;26:223-229.
- Pournaras J, Symeonides PP. The results of surgical repair of acute tears of the posterior cruciate ligament. *Clin Orthop Relat Res* 1991;267:103-107.
- Strand T, Mølster AO, Engesaeter LB, Raugstad TS, Alho A. Primary repair in posterior cruciate ligament injuries. *Acta Orthop Scand* 1984;55:545-547.
- Hughston JC, Bowden JA, Andrews JR, Norwood LA. Acute tears of the posterior cruciate ligament. Results of operative treatment. *J Bone Joint Surg Am* 1980;62:438-450.
- Wheatley WB, Martinez AE, Sacks T, et al. Arthroscopic posterior cruciate ligament repair. *Arthroscopy* 2002;18:695-702.

Table 2. Pearls and Pitfalls of PCL Repair With Suture Tape Augmentation

Pearls	Pitfalls
The ideal repair is performed within the first 4 wk after injury.	Excessive tensioning can result in difficulty achieving full extension.
The posteromedial portal is used to facilitate suture passage and helps protect residual fibers of the PCL.	Malpositioning of fixation points can constrain the joint.
Using electrosurgery to mark the fixation point on the femur ensures accuracy when the guide pin is passed.	If tissue is not adequate, additional augmentation may be required.
PCL, posterior cruciate ligament.	