

Medial Patellofemoral Ligament Repair With Suture Tape Augmentation



Graeme P. Hopper, M.B.Ch.B., M.Sc., M.R.C.S., Christiaan H. W. Heusdens, M.D.,
Lieven Dossche, M.D., and Gordon M. Mackay, M.D.

Abstract: The medial patellofemoral ligament (MPFL) is the main restraining force in the first 20° of flexion against lateral patellar displacement and is disrupted after patellar subluxation or dislocation. MPFL reconstruction is frequently performed when conservative management fails and the patient has recurrent patellar dislocations. However, a variety of complications have been reported in the literature with this procedure. Internal bracing with suture tape augmentation encourages healing and allows early mobilization. This article describes, with video illustration, MPFL repair with suture tape augmentation.

The medial patellofemoral ligament (MPFL) is the main restraining force against lateral patellar displacement in the first 20° of flexion and is often disrupted after patellar subluxation or dislocation.^{1,2} It originates at the posterior aspect of the medial epicondyle and inserts along the superomedial border of the patella.²⁻⁴

MPFL reconstruction procedures are the most widely used surgical option to address patellar instability by restoring the native length and stiffness of the medial soft tissues. However, a variety of complications with this procedure have been reported in the literature.^{1,3}

Isolated MPFL repairs have been thought to be insufficient in providing adequate functional outcomes and have been associated with a high failure rate in past literature.^{5,6} However, recent literature has seen a renewed interest in MPFL repair with acceptable results.^{7,8} We describe MPFL repair

From the Institute of Infection, Immunity and Inflammation, University of Glasgow (G.P.H.), Glasgow, Scotland; Antwerp University Hospital (C.H.W.H., L.D.), Edegem, Belgium; and University of Stirling (G.M.M.), Stirling, Scotland.

The authors report the following potential conflicts of interest or sources of funding: Arthrex has facilitated the making of the video for this surgical technique. C.H.W.H. reports that Antwerp University Hospital receives support from Research Foundation Flanders (FWO) under reference T001017N not related to this manuscript. L.D. receives support from Mathys Medical for consultancy regarding hip replacement. G.M.M. is a consultant for and receives royalties from Arthrex and has a patent for the InternalBrace. Full ICMJE author disclosure forms are available for this article online, as supplementary material.

Received July 6, 2018; accepted August 9, 2018.

Address correspondence to Graeme P. Hopper, M.B.Ch.B., M.Sc., M.R.C.S., Institute of Infection, Immunity and Inflammation, College of Medical, Veterinary and Life Sciences, University of Glasgow, 120 University Place, Glasgow, Scotland, G12 8TA. E-mail: graemehopper@nhs.net

© 2018 by the Arthroscopy Association of North America. Published by Elsevier. This is an open access article under the CC BY-NC-ND license (<http://creativecommons.org/licenses/by-nc-nd/4.0/>).

2212-6287/18844

<https://doi.org/10.1016/j.eats.2018.08.021>

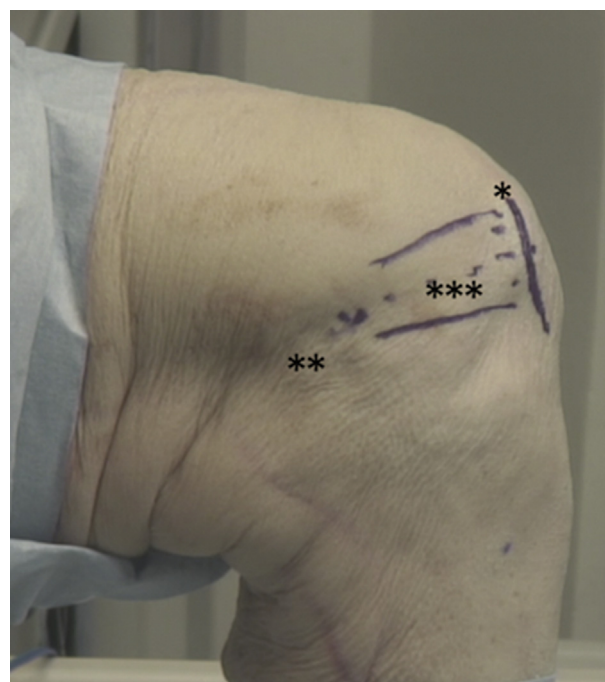


Fig 1. Left knee, medial view. The medial border of the patella (1 asterisk), medial epicondyle (2 asterisks), and medial patellofemoral ligament (3 asterisks) are shown.

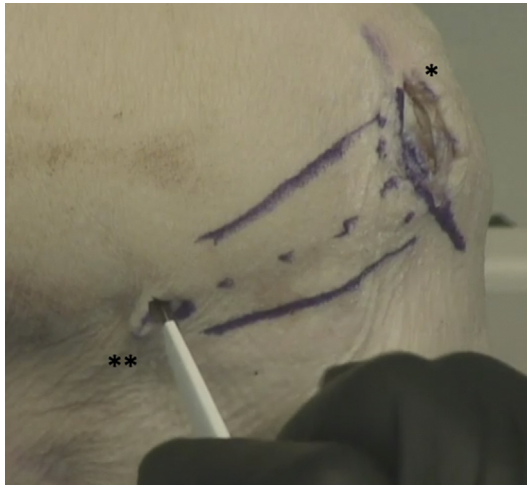

Fig 2. Left knee, medial view. A short parapatellar incision (1 asterisk) is made to expose the medial border of the patella. A stab incision (2 asterisks) is then made over the medial epicondyle.

with suture tape augmentation that encourages healing and allows early mobilization (Video 1).

Surgical Technique

The patient is placed in the supine position, and a tourniquet is placed on the upper thigh. The injured leg is prepared and draped in the surgeon's preferred position similarly to an MPFL reconstruction procedure. Appropriate landmarks are palpated and marked (Fig 1). A short parapatellar incision is made exposing the medial border of the patella. A tissue plane is established underneath the fascia and over the top of the MPFL. A second short incision is then made over the medial epicondyle (Fig 2). Adequate exposure

is obtained to ensure the correct placement of the suture tape.

The next step is to predrill with a 4.5-mm drill and tap just posterior and proximal to the medial epicondyle, with the surgeon ensuring that this is performed perpendicular to the cortex. A 4.75-mm SwiveLock (Arthrex) preloaded with FiberTape (Arthrex) is then inserted, with the surgeon ensuring it is flush with the cortex (Fig 3). The FiberTape is an ultrahigh-strength 2-mm-wide tape, consisting of long-chain ultrahigh-molecular-weight polyethylene. The suture tape is then shuttled through the previously defined tissue plane to come out through the initial incision (Fig 4).

The insertion of the MPFL on the medial border of the patella is identified. Preparation is then carried out for a 3.5-mm SwiveLock (Arthrex) by predrilling and tapping (Fig 5). It is important that the insertion point of the anchor is at the midpoint of the insertion of the MPFL at the anteromedial angle where the superior surface meets the medial wall. This allows the repair to be secured below. Primary repair of the MPFL is then performed using 2 suture anchors with FiberWire (Arthrex) inserted into the medial border of the patella with 1 above and 1 below the initial anchor (Fig 6). The 3.5-mm anchor is loaded with the suture tape, and the knee is taken through a full range of motion, with particular attention given to the tension on the suture tape during the first 20° to 30° of flexion. A hemostat can be passed gently underneath during early flexion to ensure excessive tension has not been applied. Excessive tension at this point will result in postoperative irritation and could lead to quadriceps inhibition. The suture tape is marked at the laser line during early-phase

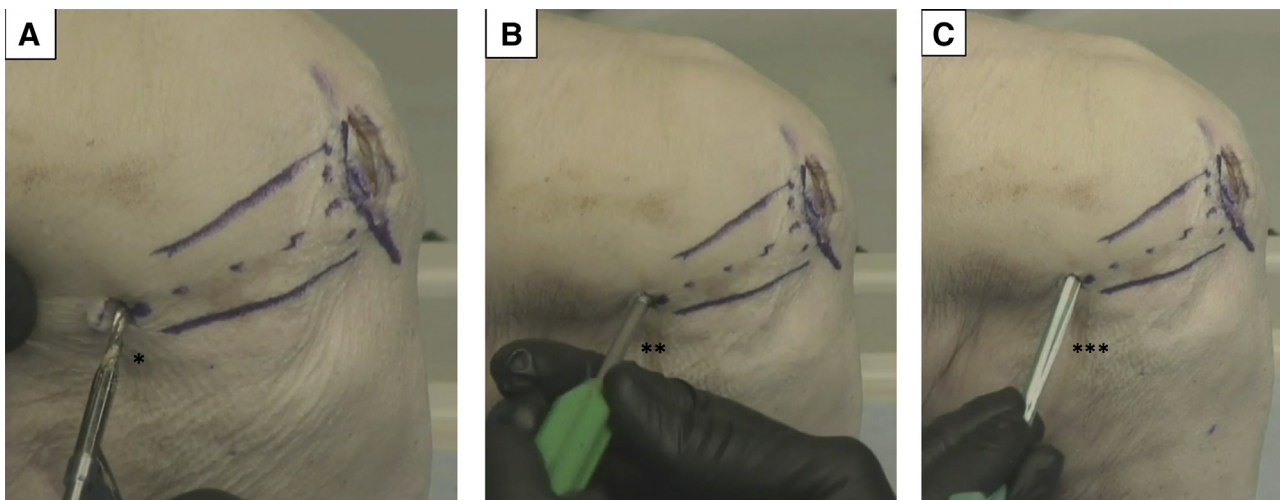


Fig 3. Left knee, medial view. (A, B) Preparation for the anchor by predrilling (1 asterisk) and tapping (2 asterisks) just posterior and proximal to the medial epicondyle. (C) The anchor preloaded with the suture tape (3 asterisks) is inserted, with the surgeon ensuring it is flush with the cortex.

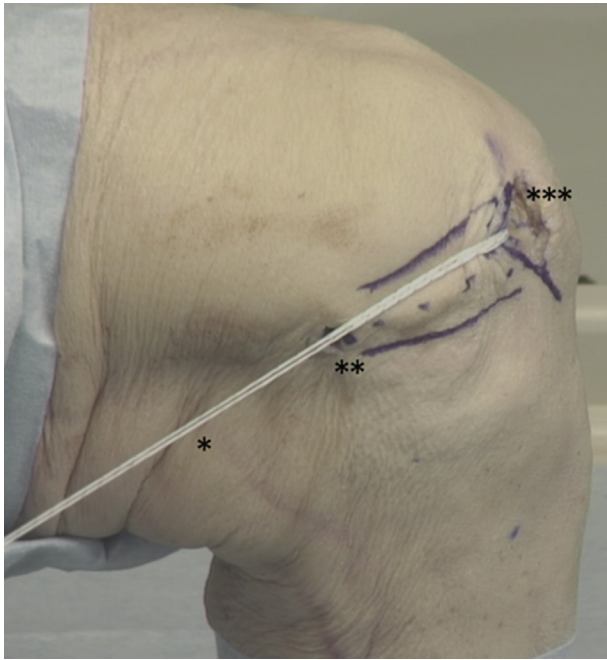


Fig 4. Left knee, medial view. The suture tape (1 asterisk) has been shuttled from the medial epicondyle (2 asterisks) toward the medial border of the patella (3 asterisks) in the direction of the medial patellofemoral ligament.

flexion to ensure that adequate length is provided and the patella is not overconstrained because this will result in pain and ongoing restriction in function. It is then repositioned in the eye of the anchor at the marked level, and finally, the anchor is placed in the drill hole (Fig 7).

The rehabilitation protocol could be compared with an accelerated MPFL reconstruction protocol. Patients are allowed to fully bear weight with crutches as required during the first few weeks. Physical therapy focuses on early range of movement, muscle control, and restoration of function. This is facilitated by the limited pain and swelling, allowing accelerated early-phase rehabilitation. Moreover, the anchor in the

dense bone of the patella and the angulation of the suture tape augmentation provide a very secure fixation that can mimic the strength of the native MPFL. Patients are allowed to perform sports if the neuromuscular function has recovered. No brace is required. Advantages and disadvantages as well as pearls and pitfalls of this technique are outlined in Tables 1 and 2.

Discussion

Multiple techniques have been described in the literature for the operative management of patients with recurrent patellar instability.^{1-7,10-14} MPFL reconstruction is the most common technique of choice; however, a number of complications have been reported in the literature.^{1,3} MPFL repair is less commonly performed owing to high failure rates reported in the literature.^{5,6}

Camp et al.⁶ described the outcomes of 27 patients who underwent MPFL repair with either suture anchors or a medial reefing technique with a minimum 2-year follow-up. In 28% of patients, a recurrent lateral patellar dislocation occurred, with 5 of these patients requiring further surgery. Camp et al. found that a significant number of recurrences were due to nonanatomic anchor placement. In addition, Arendt et al.⁵ described an MPFL repair technique using suture anchors to fix the MPFL to its origin on the femur. They retrospectively reviewed 55 knees in 48 patients with a minimum follow-up period of 2 years. Recurrent patellar dislocations occurred in 46% of patients, with 13 patients undergoing a further stabilization procedure. On the other hand, using an algorithm-based approach, at a mean follow-up of 51 months, Dragoo et al.⁷ recently compared 24 patients who underwent MPFL reconstruction or MPFL repair. They found no differences between the 2 groups, and only 1 patient in the MPFL repair group had a further dislocation.

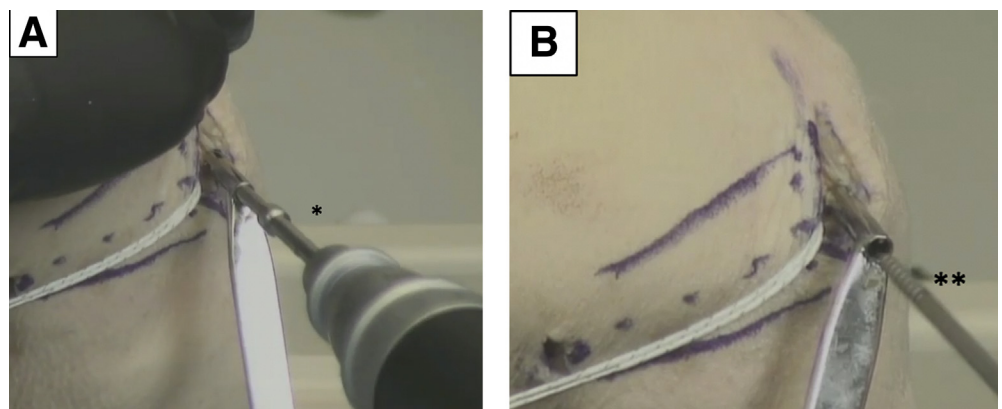


Fig 5. Left knee, medial view. (A, B) Preparation is carried out for the second anchor by predrilling (1 asterisk) and tapping (2 asterisks) at the anteromedial angle of the patella where the superior surface meets the medial wall.

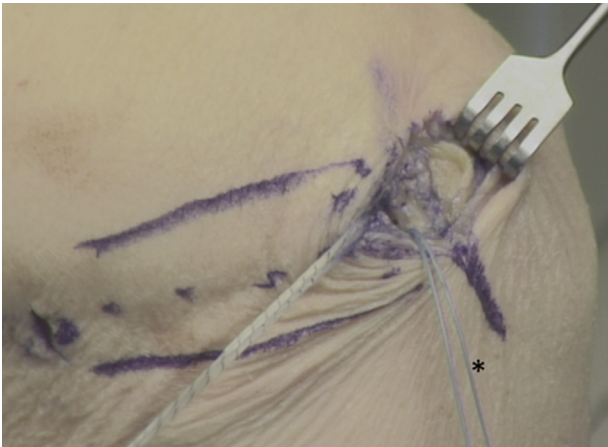


Fig 6. Left knee, medial view. Medial patellofemoral ligament repair using FiberWire (asterisk).

Several systematic reviews have been published analyzing the outcomes of MPFL reconstructions. The first review, by Smith et al.,² looked at 8 studies with 186 MPFL reconstructions and found satisfactory clinical and radiologic outcomes; however, they concluded that all of the articles had several methodologic weaknesses. Fisher et al.,¹¹ Buckens and Saris,⁴ Mackay

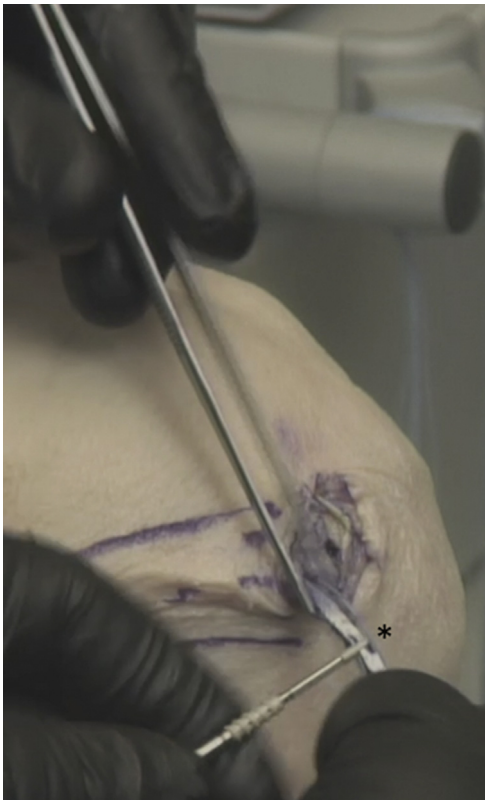

Fig 7. Left knee, medial view. The suture tape is repositioned in the eye of the anchor at the marked level (asterisk) to ensure that the anatomic length of the medial patellofemoral ligament is restored.

Table 1. Advantages and Disadvantages of Medial Patellofemoral Ligament Repair With Suture Tape Augmentation

Advantages	Disadvantages
Simple and reproducible	Synthetic augmentation
No graft harvest required	Medial epicondyle tenderness
Facilitates rehabilitation	
Minimal surgical morbidity	

et al.,¹⁰ and Tompkins and Arendt¹³ have since reported similar conclusions. Schneider et al.¹² performed a systematic review and meta-analysis to look more specifically at return to sport after MPFL reconstructions. They reported encouraging results, with 84.1% of patients returning to sports postoperatively with a low incidence of recurrent instability. On the other hand, Shah et al.³ reviewed 25 articles and found a complication rate of 26.1%, with 26 patients requiring further surgery.

MPFL repair with suture tape augmentation as described in this Technical Note reinforces the ligament and acts as a secondary stabilizer. This promotes natural healing by protecting the ligament during the healing phase, as well as allowing early mobilization. Furthermore, it does not require the use of a graft, thereby avoiding the unnecessary morbidity of graft harvest. In addition, with protection of the ligament by the suture tape augmentation, complications previously associated with MPFL repair may be avoided. However, it is important to ensure that the suture tape is not over-constrained and is tensioned in the first 20° to 30° of flexion. Excess tensioning can lead to irritation and may result in quadriceps inhibition (Tables 1 and 2).

In conclusion, this Technical Note has discussed the technique of MPFL repair with suture tape augmentation. Several advantages are associated with this technique as outlined earlier, and we have observed excellent clinical results. However, further clinical studies are necessary to determine the overall outcomes of this procedure.

Table 2. Pearls and Pitfalls of Medial Patellofemoral Ligament Repair With Suture Tape Augmentation

Pearls	Pitfalls
The use of ultrasound may give some surgeons additional confidence when identifying the medial epicondyle. ⁹	It is important to establish anatomic accuracy.
The surgeon should ensure that excessive constraint is not applied.	Excessive tension will result in postoperative irritation and may lead to quadriceps inhibition.
The suture tape should be tensioned during the first 20°-30° of flexion.	

References

1. Hopper GP, Leach WJ, Rooney BP, Walker CR, Blyth MJ. Does degree of trochlear dysplasia and position of femoral tunnel influence outcome after medial patellofemoral ligament reconstruction? *Am J Sports Med* 2014;42:716-722.
2. Smith TO, Walker J, Russell N. Outcomes of medial patellofemoral ligament reconstruction for patellar instability: A systematic review. *Knee Surg Sports Traumatol Arthrosc* 2007;15:1301-1314.
3. Shah JN, Howard JS, Flanigan DC, Brophy RH, Carey JL, Lattermann C. A systematic review of complications and failures associated with medial patellofemoral ligament reconstruction for recurrent patellar dislocation. *Am J Sports Med* 2012;40:1916-1923.
4. Buckens CF, Saris DB. Reconstruction of the medial patellofemoral ligament for treatment of patellofemoral instability: A systematic review. *Am J Sports Med* 2010;38:181-188.
5. Arendt EA, Moeller A, Agel J. Clinical outcomes of medial patellofemoral ligament repair in recurrent (chronic) lateral patella dislocations. *Knee Surg Sports Traumatol Arthrosc* 2011;19:1909-1914.
6. Camp CL, Krych AJ, Dahm DL, Levy BA, Stuart MJ. Medial patellofemoral ligament repair for recurrent patellar dislocation. *Am J Sports Med* 2010;38:2248-2254.
7. Dragoo JL, Nguyen M, Gatewood CT, Taunton JD, Young S. Medial patellofemoral ligament repair versus reconstruction for recurrent patellar instability: Two-year results of an algorithm-based approach. *Orthop J Sports Med* 2017;5. 2325967116689465.
8. Mackay GM, Blyth MJ, Anthony I, Hopper GP, Ribbans WJ. A review of ligament augmentation with the InternalBrace™: The surgical principle is described for the lateral ankle ligament and ACL repair in particular, and a comprehensive review of other surgical applications and techniques is presented. *Surg Technol Int* 2015;26:239-255.
9. Hirahara AM, Mackay G, Andersen WJ. Ultrasound-guided suture tape augmentation and stabilization of the medial collateral ligament. *Arthrosc Tech* 2018;7:e205-e210.
10. Mackay ND, Smith NA, Parsons N, Spalding T, Thompson P, Sprowson AP. Medial patellofemoral ligament reconstruction for patellar dislocation: A systematic review. *Orthop J Sports Med* 2014;2. 2325967114544021.
11. Fisher B, Nyland J, Brand E, Curtin B. Medial patellofemoral ligament reconstruction for recurrent patellar dislocation: A systematic review including rehabilitation and return-to-sports efficacy. *Arthroscopy* 2010;26:1384-1394.
12. Schneider DK, Grawe B, Magnussen RA, et al. Outcomes after isolated medial patellofemoral ligament reconstruction for the treatment of recurrent lateral patellar dislocations: A systematic review and meta-analysis. *Am J Sports Med* 2016;44:2993-3005.
13. Tompkins MA, Arendt EA. Patellar instability factors in isolated medial patellofemoral ligament reconstructions—What does the literature tell us? A systematic review. *Am J Sports Med* 2015;43:2318-2327.
14. Matic GT, Magnussen RA, Kolovich GP, Flanigan DC. Return to activity after medial patellofemoral ligament repair or reconstruction. *Arthroscopy* 2014;30:1018-1025.